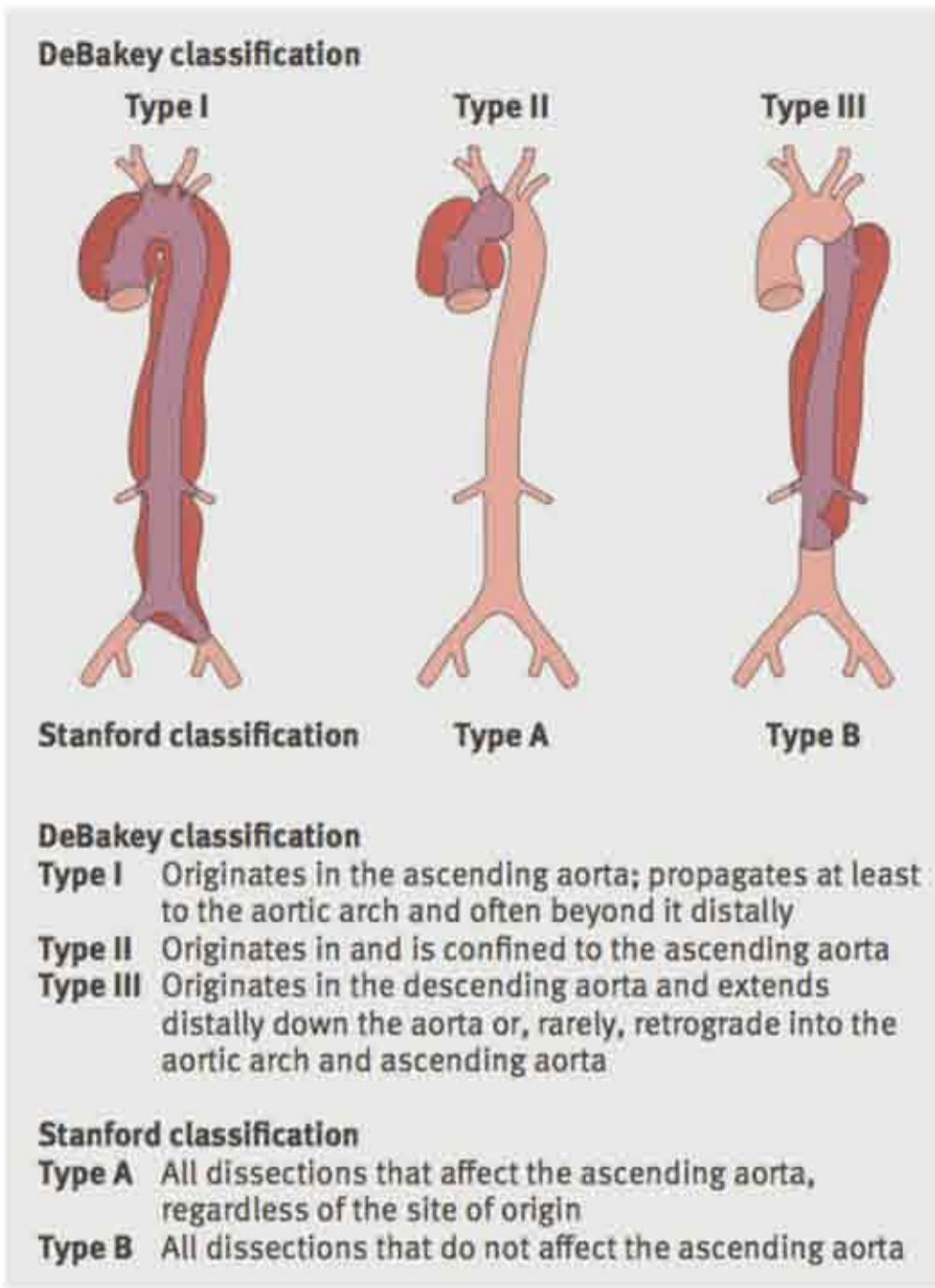


**Introduction:**

Acute aortic dissection type A requires immediate surgical repair. The aim of surgery is to prevent aortic rupture, pericardial tamponade, and to relieve aortic regurgitation.

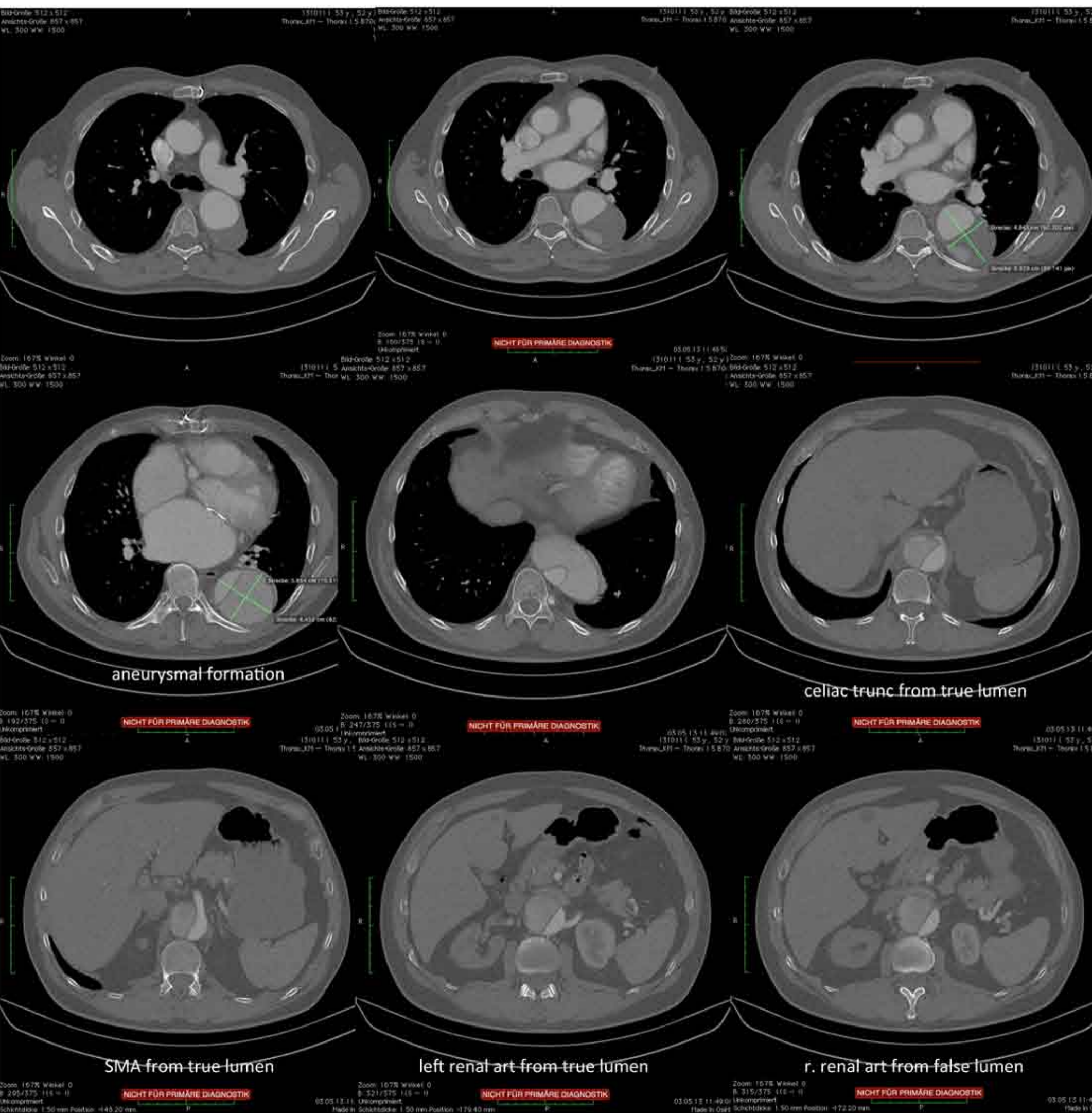In type B dissection like in all aortic dissections medical therapy with blood pressure control and pain relief is recommended. If no complications are present the mortality with TEVAR and BMT are comparable. Only in complicated type B dissections TEVAR is recommended and superior to open repair. From the IRAD data we know that there is a low rate of false lumen thrombosis and over time an increase in aortic diameter with aneurysmal formation and a high mortality over time in these often younger patients.

In this case of a 53yr patient with chronic type B dissection since 2 yrs we want to show the problems and difficulties with endovascular treatment which requires often staged procedures and repair of the complete descending thoracic and abdominal aorta with endovascular techniques.



**Patient data:**

Male patient, born 1960, in June 2011 acute aortic dissection type B Stanford Typ III DeBakey no complications under medical treatment and blood pressure control. No connective tissue disease. In his previous history 2003 replacement of the aortic root and repair of aortic and mitral valve with Duran ring 31mm. Cardiovascular risk: arterial hypertension, nicotine, hypertensive cardiomyopathy and LV hypertrophy 2013 atrial fibrillation, cardioversion and sinus rhythm with amiodarone. In the follow up controls increase of aortic diameter and aneurysmal formation, persisting perfusion of the false lumen with indication for surgery



Preop CT: proximal entry distal of LSA, celiac trunc, SMA and left renal artery originating from the true lumen, right renal from the false lumen, extension of the dissection in the right iliac axis

# Complete TEVAR in chronic aneurysmatic type B dissection

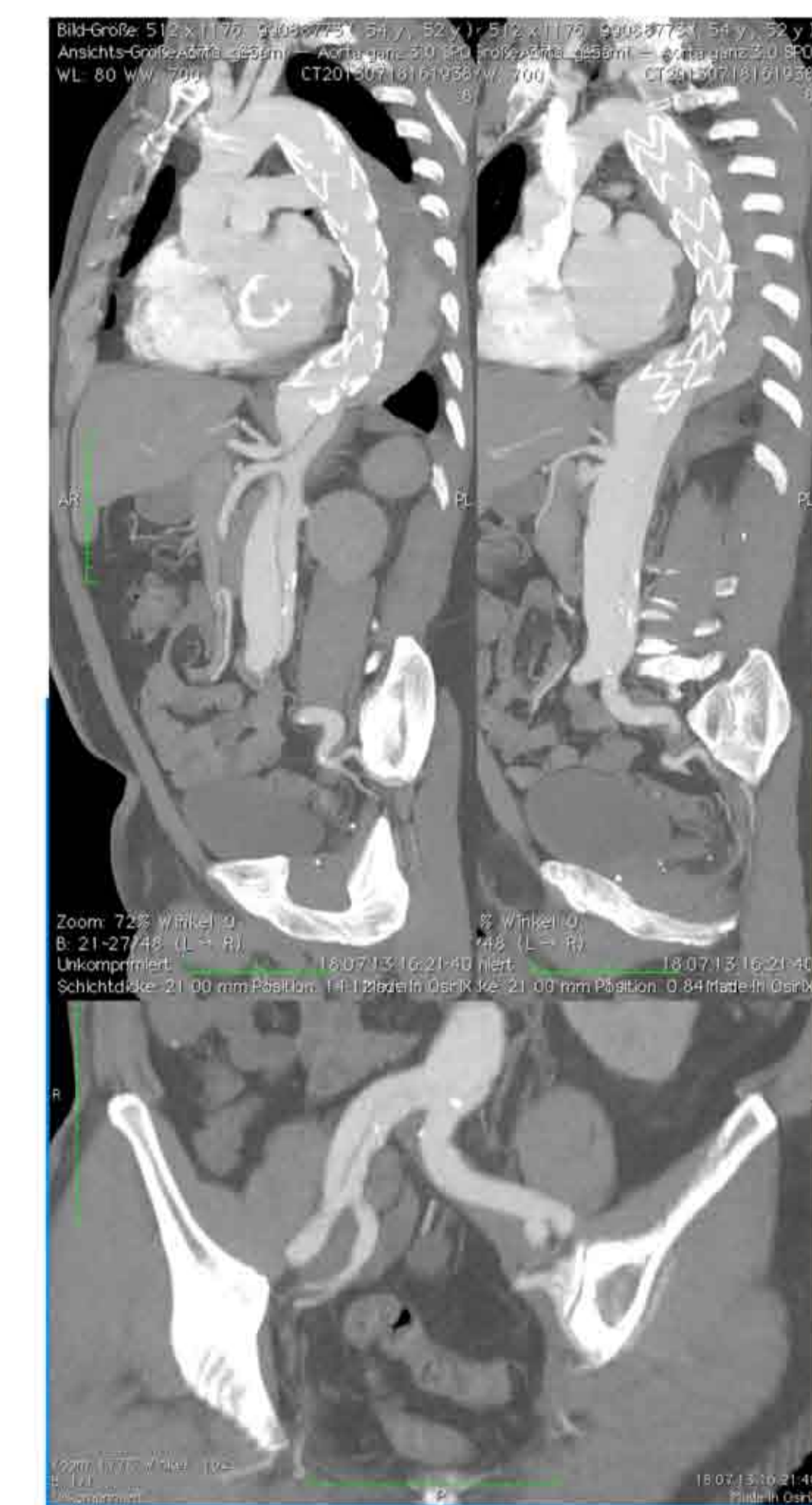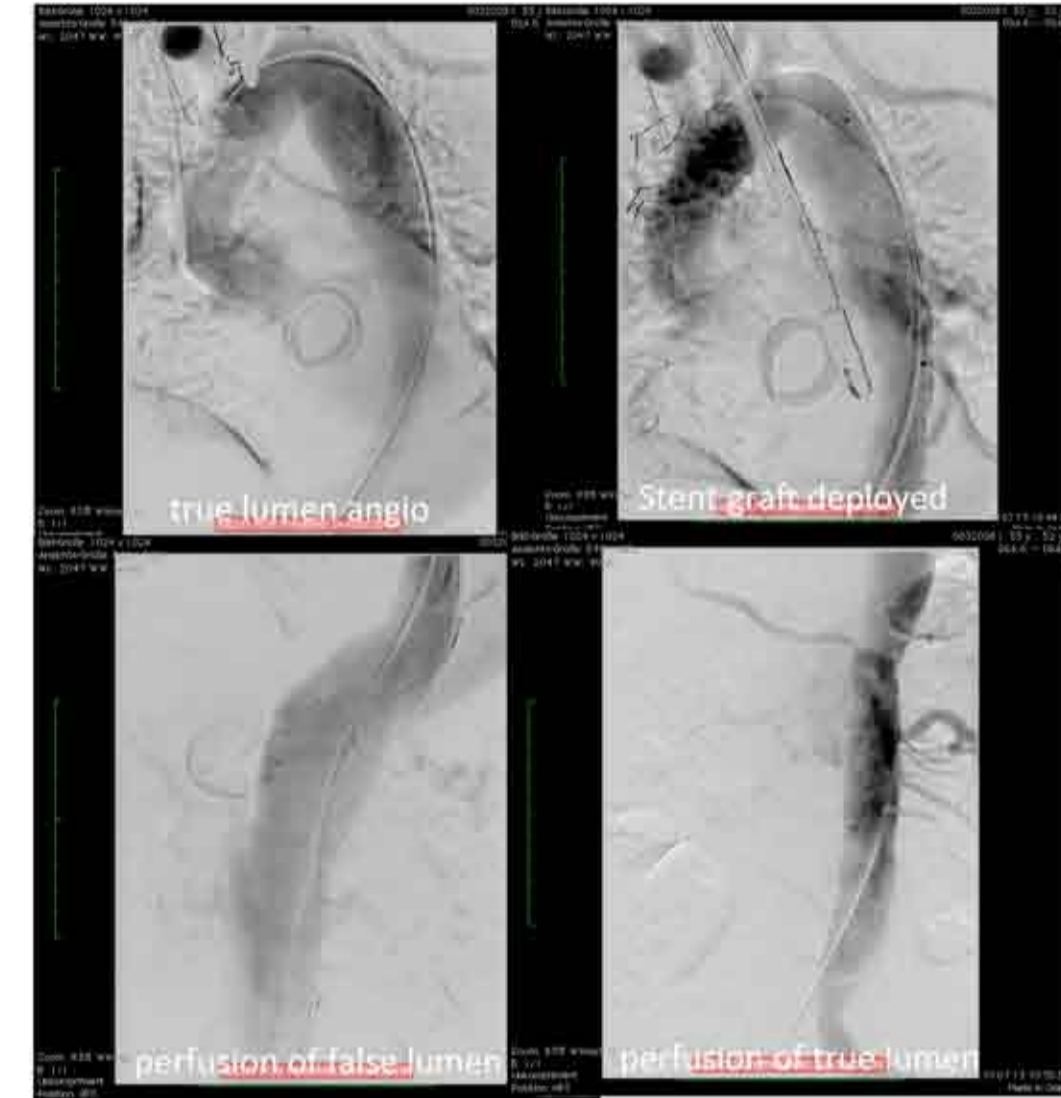
a typical case report

Rolf A. Dammrau, Practice for Vascular and Thoracic Surgery, 52399 Merzenich, Germany

**1st surgery July 2013**

To close the proximal big entry tear in the descending aorta TEVAR was performed. Proximal diameter was bigger, because of the small true lumen it was planned a tapered graft thoracoabdominal Jotec E-vita thoracic, proximal diameter 40mm, distal 33mm, length 230mm with placement distal of the LSA. Confirmation of the guide wire in the true lumen with TEE guidance, proximal good apposition but distal unintentionally end of the graft in the false lumen. But perfusion of all visceral vessels. Expansion of true lumen in the thoracic part

Angio intraop

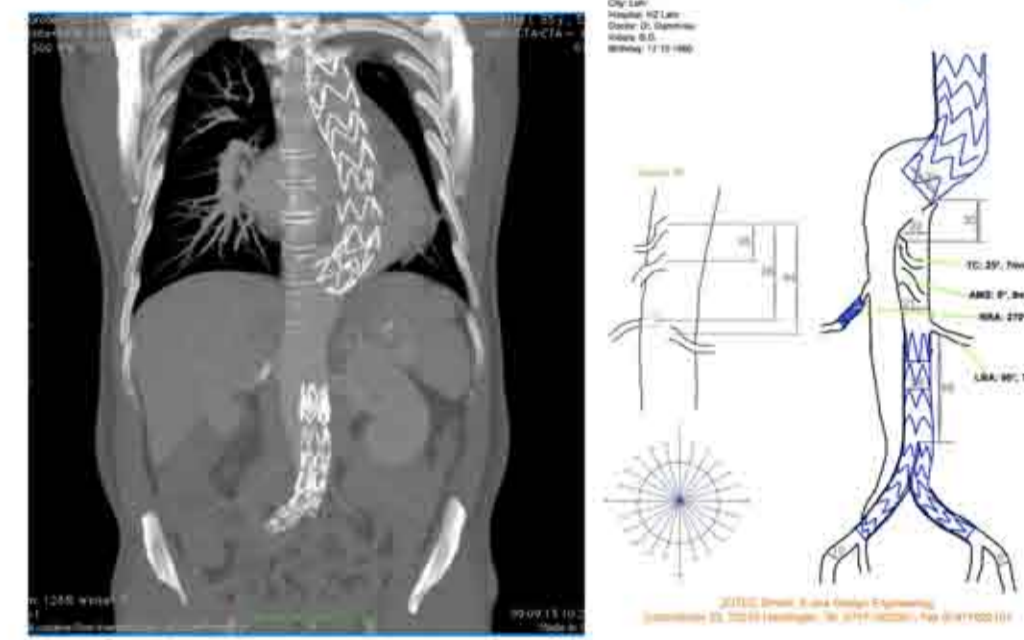


Postop CT after TEVAR, distal end of the stent graft in the false lumen, all visceral vessels originating from the true lumen, only right renal artery perfused from the false lumen. Right iliac arteries perfused from the false lumen. Still retrograde perfusion into the thoracic aneurysm

**2nd surgery September 2013**

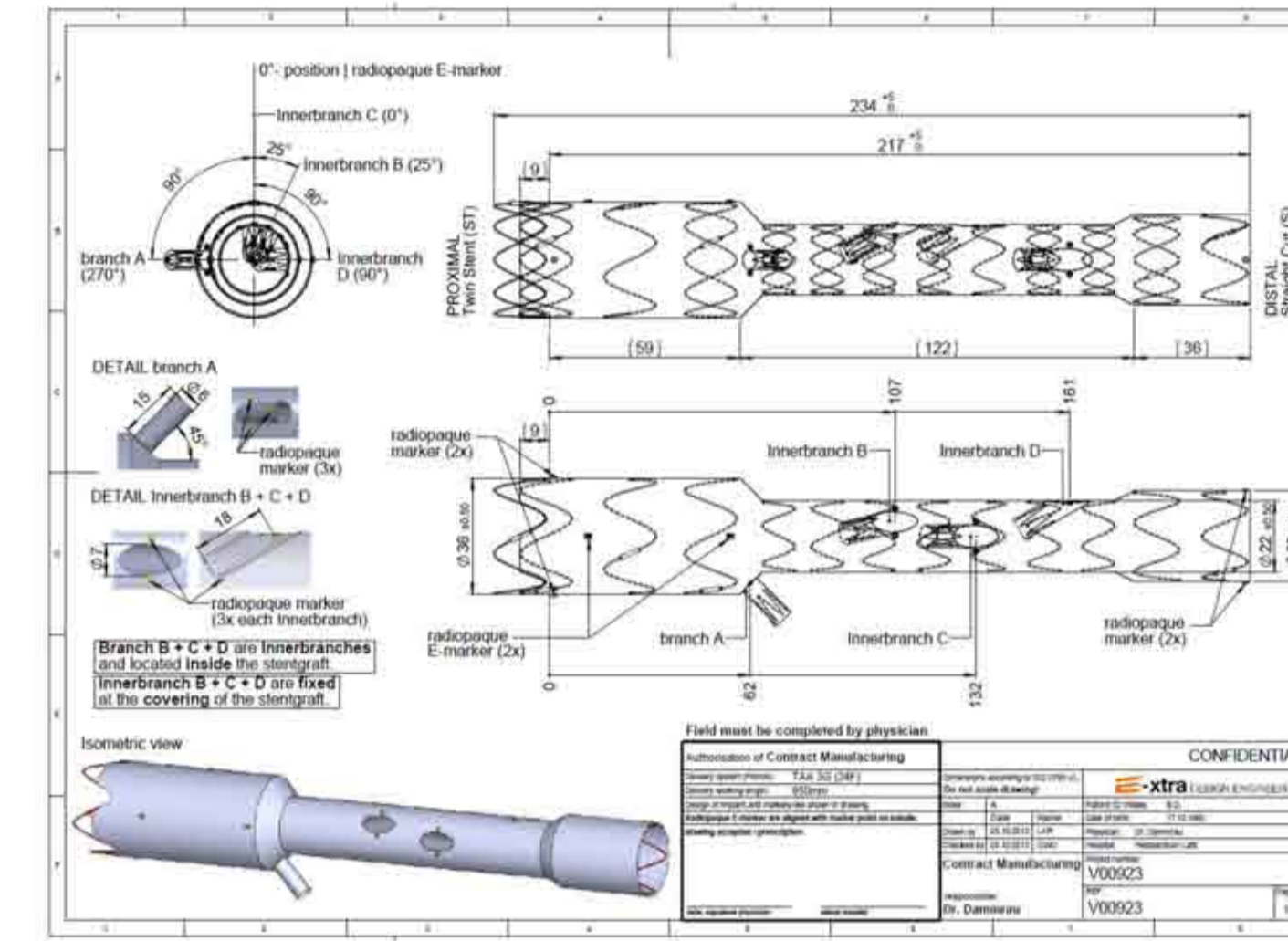
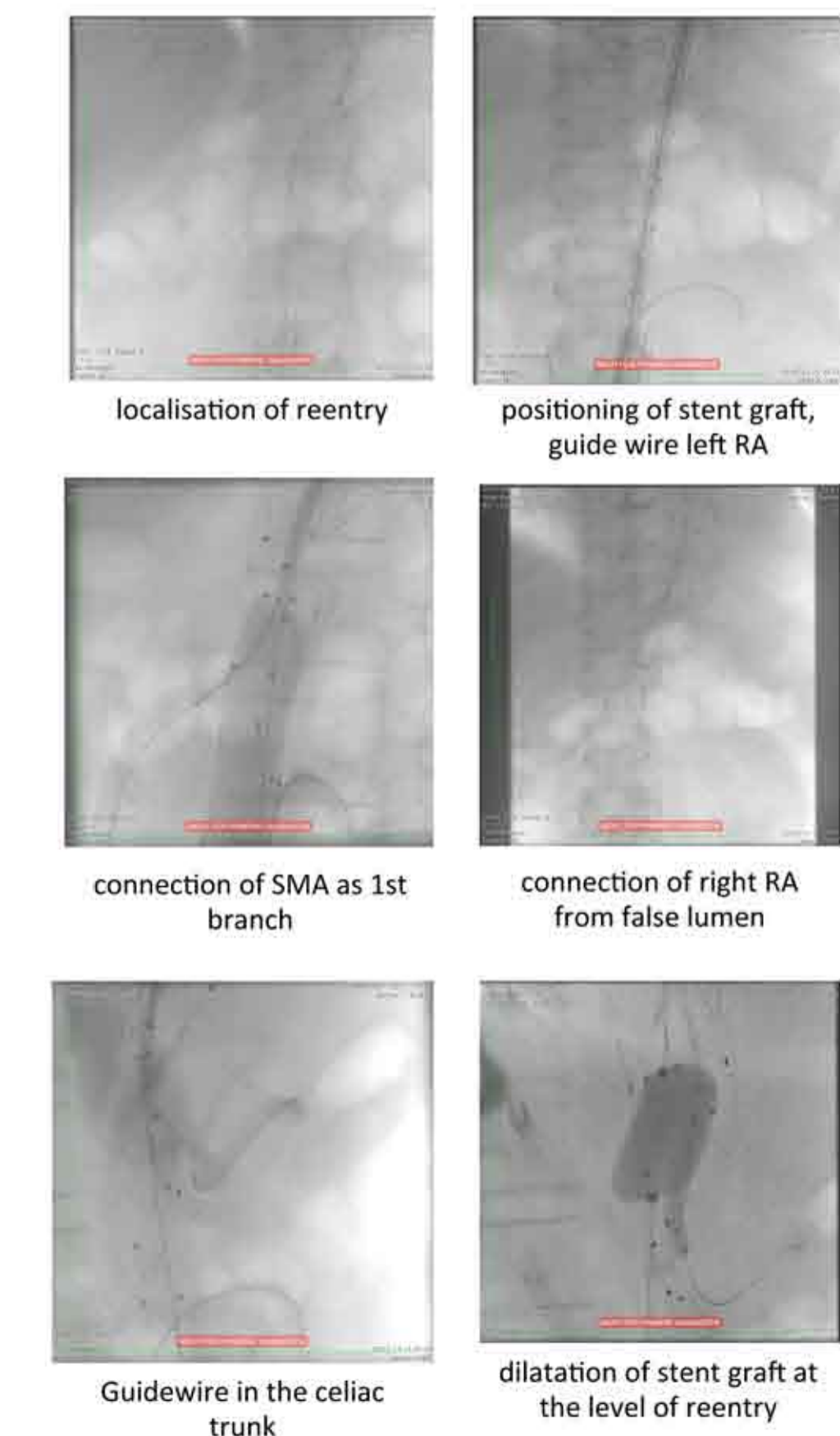
EVAR with infrarenal bi-iliacal stent graft (Jotec E-vita). The stent graft was placed in the true lumen so both iliac arteries were perfused by the true lumen. Additional dilatation of the reentry between the lumina and stenting of the right renal artery from the false lumen was performed

**3rd surgery March 2014**

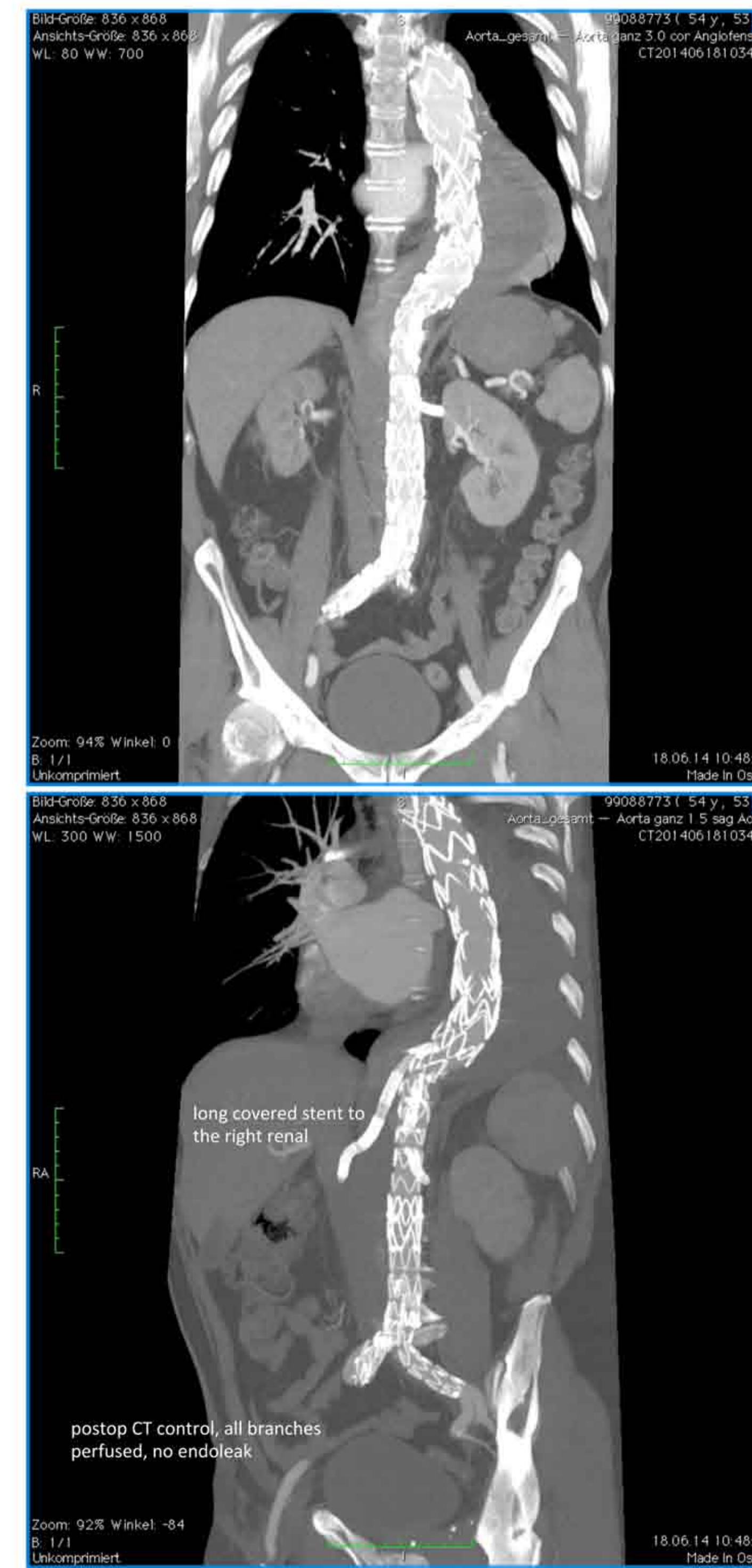


Next planned procedure is connection between thoracoabdominal graft, for visceral segment 4 branches. Due to limited space in the true lumen the celiac trunk, SMA and left renal with inner branches and the right renal with outer branch

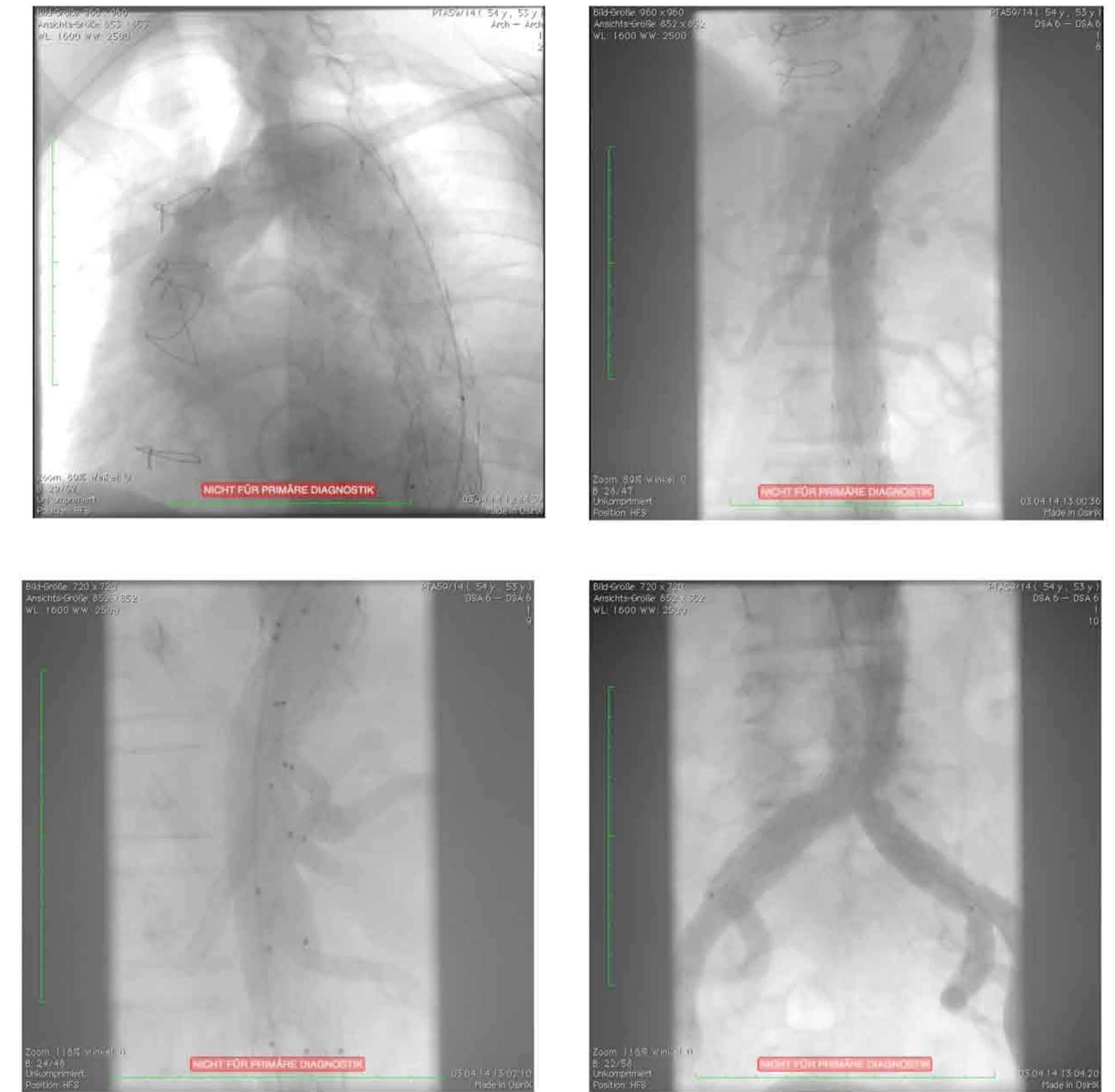
Custom made branched graft Jotec Extra design. Access from the femoral arteries and left axillary artery. With pull thru wire crossing the reentry and positioning of the branched graft, so the proximal branch opens in the false lumen. Positioning according to the guide wire in the renal. Connection of the branches with Eventus covered stents. At the level of the lamella dilatation necessary to open the graft to ist diameter. For the right renal artery several covered stents necessary. Good final result. Postop good recovery, no major complications



Technical drawing, 1 outer, 3 inner branches



final angiographic results, stent graft in position, no endoleak, all branches perfused



**Discussion and Conclusion:**

TEVAR is well established for complicated type B dissections. In this typical case of type B aortic dissection the patient developed aneurysmal formation with dilatation more of the false lumen. As complicated case there was indication for surgery, preferred endovascular. Here in chronic cases the treatment is more complex, the size of the aorta is usually bigger, expansion of the true lumen is often difficult or impossible due to the stiffness of the lamella. Landing zone may be in the arch or thoracoabdominal aorta, if branched grafts are needed there is often not sufficient space. Debranching or hybrid procedures are more frequent necessary in chronic cases. In extended dissection often staged procedures are necessary. This may even reduce the risk of paraplegia. Here we landed with the 1st TEVAR in the false lumen, perhaps with the use of IVUS we could prevent this. On the other hand the right renal from the false lumen could be lost by excluding the false lumen complete. But for the treatment of the thoracoabdominal segment with the origin of the visceral arteries it is necessary to use fenestrated or branched grafts. The Jotec Extra Design Engineering offers a wide range of individual solutions to treat even difficult anatomies. A delivery time of 18 working days is tolerable in most cases. Endovascular treatment of acute type B dissections shows similar survival as BMT like in the IRAD registry or in the first two years of INSTEAD Trial. After this observation period there is advantage for the endovascular group. The ADSORB trial is demonstrated a good remodeling of the aorta with TEVAR in the acute dissection. There are factors like size of the main entry tear, a partial false lumen thrombosis and the initial false lumen diameter the development of late complications. Beside of life long surveillance we have to identify them earlier and treat these patients when it is possible with less complex procedures.

**References:**

- Complicated Acute Type B Dissections: Is Surgery Still the Best Option?: A Report from the International Registry of Acute Aortic Dissection Fattori R, JACC Intv 2008; 1: 395
- Endovascular repair of Type B Aortic Dissection: Long-Term Results of the Randomized Investigation of Stent Grafts in Aortic Dissection Trial Nienaber CA et al. Circ Cardiovasc Interv 2013;6:407-416
- Interdisciplinary expert consensus document on management of type B aortic dissection Fattori R. J Am Coll Cardiol 2013 Apr 23 23;61(16):1661-78
- Medical management in type B aortic dissection Suzuki T Ann Cardiothorac Surg 2014;3(4):413-417
- 2014 ESC Guidelines on the diagnosis and treatment of aortic diseases European Heart Journal Aug 29,2014
- Endovascular Repair of Acute Uncomplicated Aortic Type B Dissection Promotes Aortic Remodelling: 1 Year Results of the ADSORB Trial Brunkwall J Eur J Vasc Endovasc Surg 2014 Sep;48(3):285-91